



# Rigid bronchoscopic intervention for malignant central airway obstruction

## A narrative review

Byeong-Ho Jeong<sup>1,2</sup>, Hojoong Kim<sup>1</sup>

<sup>1</sup>Division of Pulmonary and Critical Care Medicine, Department of Medicine, Samsung Medical Center, Sungkyunkwan University School of Medicine, Seoul, Korea

<sup>2</sup>Department of Medicine, University of California San Diego, La Jolla, CA, USA

Received: August 29, 2023

Revised: August 31, 2023

Accepted: September 5, 2023

### Corresponding author:

Hojoong Kim

Division of Pulmonary and Critical Care Medicine, Department of Medicine, Samsung Medical Center, Sungkyunkwan University School of Medicine, 81 Irwon-ro, Gangnam-gu, Seoul 06351, Korea  
Tel: +82-2-3410-3429

E-mail: [hj3425.kim@samsung.com](mailto:hj3425.kim@samsung.com)

## ABSTRACT

As the overall survival of patients with cancer has increased over the past decade, the need for bronchoscopic intervention to resolve malignant central airway obstruction (MCAO) has correspondingly increased. The response to chemotherapy and radiotherapy is slow and cannot be guaranteed to adequately address MCAO. Surgery is often impossible because of the extent of disease or the poor performance status of patients. Bronchoscopic intervention results in immediate therapeutic response and is considered safe. Accordingly, many interventional pulmonologists and oncologists are interested in this field, but it is challenging and detailed techniques are not properly standardized, which are barriers to entry into this field. This review aimed to explore the indications and clinical applications of bronchoscopic intervention for patients with MCAO using previously reported data and representative cases from our pioneering experiences. In particular, we focused on rigid bronchoscopy for MCAO, excluding procedures for fistulas or radiation-induced bronchitis stenosis that occurred secondary to anti-cancer treatment.

**Keywords:** Airway obstruction; Bronchoscopy; Lung neoplasms

## INTRODUCTION

The first interventional bronchoscopy, known as airway foreign body removal, was performed in 1897 by Gustav Killian, and the main techniques of modern interventional bronchoscopy, including laser therapy and stent insertion, were developed by Jean-François Dumon in the 1980s and 1990s [1-4]. Although interventional bronchoscopy can be performed using a flexible bronchoscope, interventional pulmonologists prefer to perform rigid bronchoscopy rather than flexible bronchoscopy. Rigid bronchoscopy possesses several advantages over flexible bronchoscopy, such as better airway control and greater capability for suction. Most importantly, some major techniques, such as silicone stent insertion and mechanical debulking are only possible with rigid bronchoscopy [3-5]. Despite the disadvantages of rigid bronchoscopy, such as the require-

This is an Open Access article distributed under the terms of the Creative Commons Attribution Non-Commercial License (<https://creativecommons.org/licenses/by-nc/4.0/>).

ment for general anesthesia and the challenges associated with performing the procedure, it continues to play a vital role in interventional pulmonology. Experts recommend that interventional bronchoscopy should be performed with rigid bronchoscopy as far as possible. Therefore, this narrative review explores interventional bronchoscopy using only rigid bronchoscopy.

In Korea, Professor Hojoong Kim began performing interventional bronchoscopy in earnest in 1999 [6]. A multicenter retrospective study conducted at 14 hospitals in Korea, indicated that rigid bronchoscopy has recently been widely performed at many hospitals [7]. It was actively implemented only at the Samsung Medical Center (SMC) in 2003 to 2005; however, over 14 hospitals implemented the procedure during 2018 to 2020, and the proportion of new patients accounted for by the SMC steadily decreased from 100% to 59%. Nevertheless, the disparity persisted, as 59% of new patients nationwide were still treated at the SMC. According to the results of an online survey of 14 operators, the absence of a supervisor was ranked second as an obstacle to initiating rigid bronchoscopy. Engaging in discussions with experts and long-term training at a hospital where many rigid bronchoscopies are performed were suggested as strategies for juniors interested in performing rigid bronchoscopy [7]. Although many pulmonologists are convinced of the need for rigid bronchoscopy, high barriers of entry into the procedure remain [5]. In this narrative review, we discuss important issues that should be considered when performing the procedure for malignant central airway obstruction (MCAO), which is the most common indication for rigid bronchoscopy [7], to reduce the entry barriers to this procedure as much as possible.

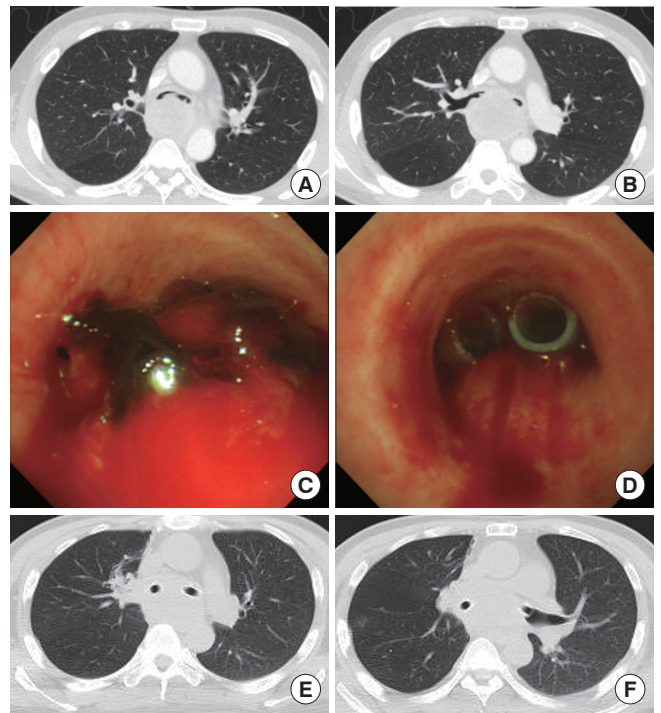
## WHAT IS THE INCIDENCE OF MALIGNANT CENTRAL AIRWAY OBSTRUCTION?

In interventional pulmonology, the central airway is usually defined as the trachea to the main bronchi, including the bronchus intermedius, and sometimes includes the lobar bronchus, depending on individual circumstances. This is because the difficulty of the procedure increases, and its clinical importance decreases if the obstruction is more distal than the lobar bronchus [8,9]. In general, clinical symptoms such as dyspnea occur when the central airway narrowing exceeds 50% of its cross-sectional area [10]; therefore, cases with central airway narrowing greater than 50% is defined as central airway obstruction (CAO).

CAO may occur in over 20% of all patients as the first diag-

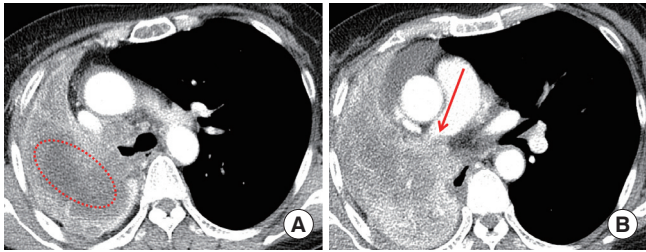
nosis of cancer, or cancer progression during treatment, not only in primary lung cancer but also in pulmonary metastasis of extrapulmonary malignancies [11,12]. According to the annual report of cancer statistics in Korea in 2019, the 5-year relative survival rate of patients with lung cancer increased from 12.5% (1993–1995) to 34.7% (2015–2019) in approximately 20 years [13]. As the cancer survival rate increases, the frequency of CAO requiring rigid bronchoscopy increases correspondingly [7]. While the number of new patients undergoing rigid bronchoscopy at 14 hospitals in Korea increased from 189 in 2003–2005 to 791 in 2018–2020, the proportion of cases with MCAO steadily increased from 29% (55/189) to 43% (340/791) [7].

MCAO can cause atelectasis, respiratory distress, and obstructive pneumonia [14]. Hence, radiation therapy to the af-



**Fig. 1.** A representative case with malignant central airway obstruction (MCAO) limited to the central airway without complete obstruction of the airway and complete atelectasis of the lung. A 43-year-old man with liver metastases of lung cancer (adenocarcinoma) was admitted to the intensive care unit (ICU) due to dyspnea during third-line chemotherapy. (A, B) The patient had a MCAO from the distal trachea to both main bronchi and bronchus intermedius and his vital signs were unstable, so we performed rigid bronchoscopy at the ICU bedside. (C, D) The tumor inside the airway was removed using a rigid bronchoscope (mechanical debridement), and extrinsic compression by the bulky mediastinal lymph nodes was resolved by inserting silicone stents into both main bronchi. (E, F) After the procedure, chest images confirmed that the airway was well secured.

ected area, surgical resection of the tumor, and systemic chemotherapy should be considered. However, patients do not respond immediately to radiation therapy and chemotherapy, and surgical resection is often impossible because of the patient's poor general condition or advanced disease status. In such situations, interventional bronchoscopy can pro-

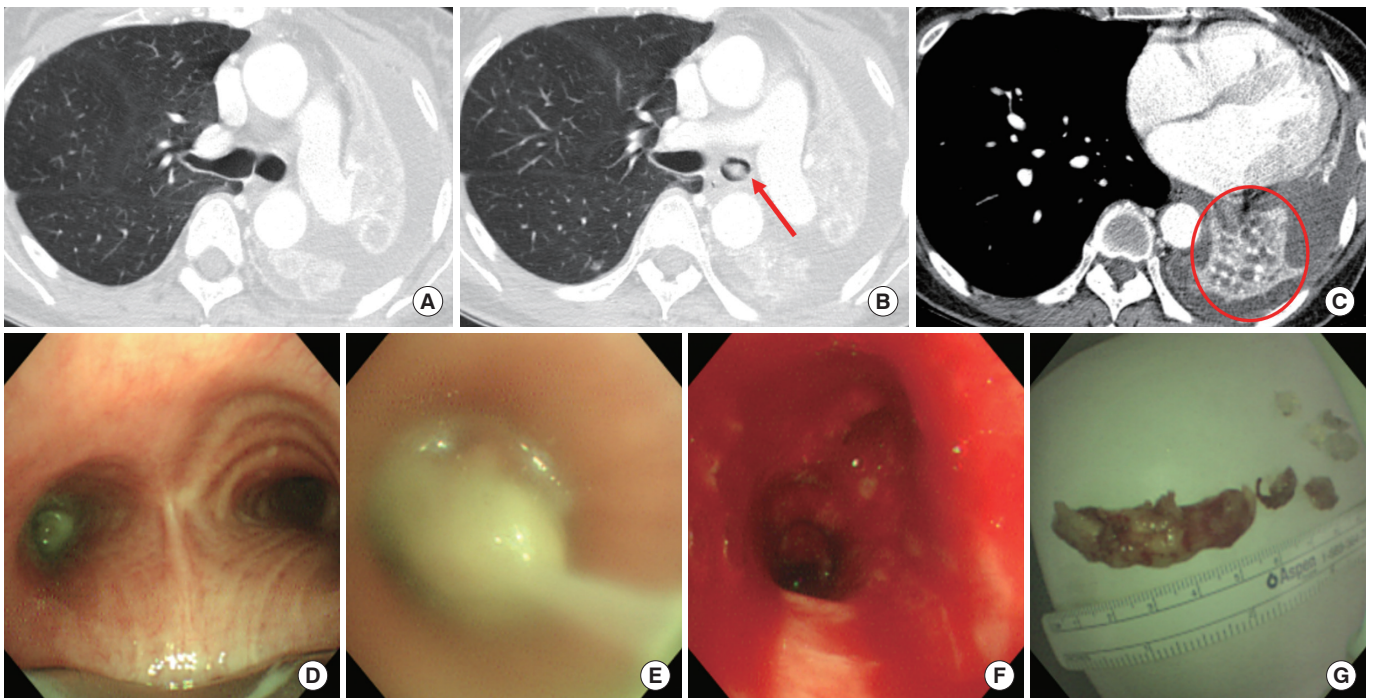


**Fig. 2.** A representative case unsuitable for bronchoscopic intervention. A 56-year-old woman with lung cancer (squamous cell carcinoma, T2N2M0) refused treatment. After 6 months, she visited the emergency room due to worsening dyspnea. A significant portion of the lung parenchyma was already necrotic (A, red dotted ellipse) and a cut-off sign of the right pulmonary artery trunk (B, red arrow) was observed on enhanced images, which was not a condition that could be resolved by bronchoscopic intervention.

vide immediate and effective treatment. Nevertheless, this procedure may not be helpful for all patients with MCAO. To determine the patients for whom the procedure is technically feasible and those who will clinically benefit, a clear understanding of the governing principles is required.

### WHEN IS THE PROCEDURE “TECHNICALLY FEASIBLE”?

First, it is necessary to assess whether the lung parenchyma will be well secured and to confirm that there will be no problems with circulation to the lung parenchyma when the MCAO is resolved. This evaluation is relatively easy if the airway is not totally obstructed or complete atelectasis of the lungs does not occur (Fig. 1). If complete atelectasis of the lungs and total obstruction of the airway occur, contrast-enhanced computed tomography (CT) should be performed first. Moreover, since bronchoscopic intervention can only resolve issues regarding the inside of the airway, there should be no necrosis of the lung parenchyma and no cut-off sign of the vessels on contrast-enhanced CT (Fig. 2). Conversely, even in



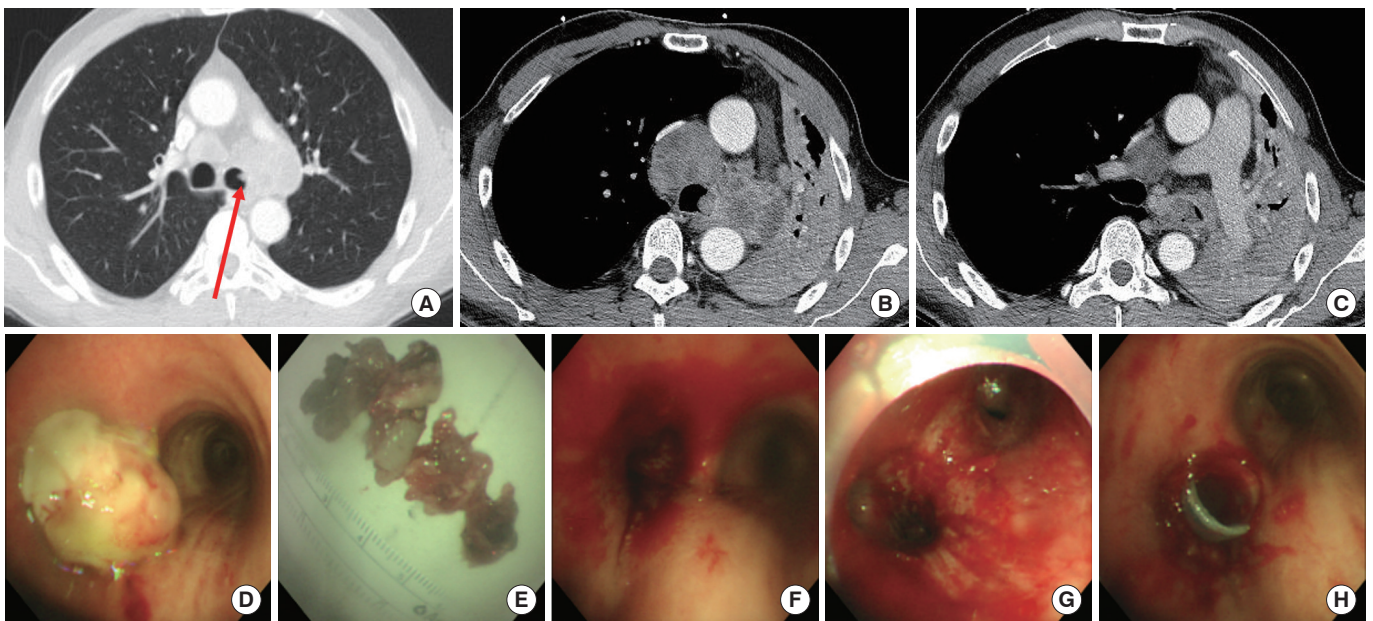
**Fig. 3.** A representative case suitable for rigid bronchoscopy even in patients with complete atelectasis. A 59-year-old woman with renal cell carcinoma was hospitalized due to increased dyspnea with complete collapse of the left lung. (A, B) Chest computed tomography (CT) revealed that the left main bronchus was completely blocked from the midpoint (red arrow). (C) However, the chest CT showed pulmonary vessels with contrast enhancement (red circle), suggesting that blood circulation was maintained. In addition, secretions inside the airway and no necrosis of the lung parenchyma were found (red circle), suggesting that there were no problems in the peripheral airway and lung parenchyma. (D, E) Similar to the CT findings, rigid bronchoscopy showed complete obstruction from the midpoint of the left main bronchus. (F, G) The left main and left lower bronchi were secured by removing the tumor mass inside the airway.

the case of a completely collapsed lung, bronchoscopic intervention can be considered if there are non-enhanced materials and secretions inside the airway (mucus plugging) and well-enhanced vessel shadows within the collapsed lung (Fig. 3). In addition, it is important to determine when the collapse occurred by referring to recent chest images. Some studies have shown that the success rate of the procedure is low if atelectasis lasts > 1 to 2 months in patients with benign stenosis [15]. Similarly, in patients with MCAO, if the atelectasis is prolonged, the procedure is not possible (Figs. 4, 5).

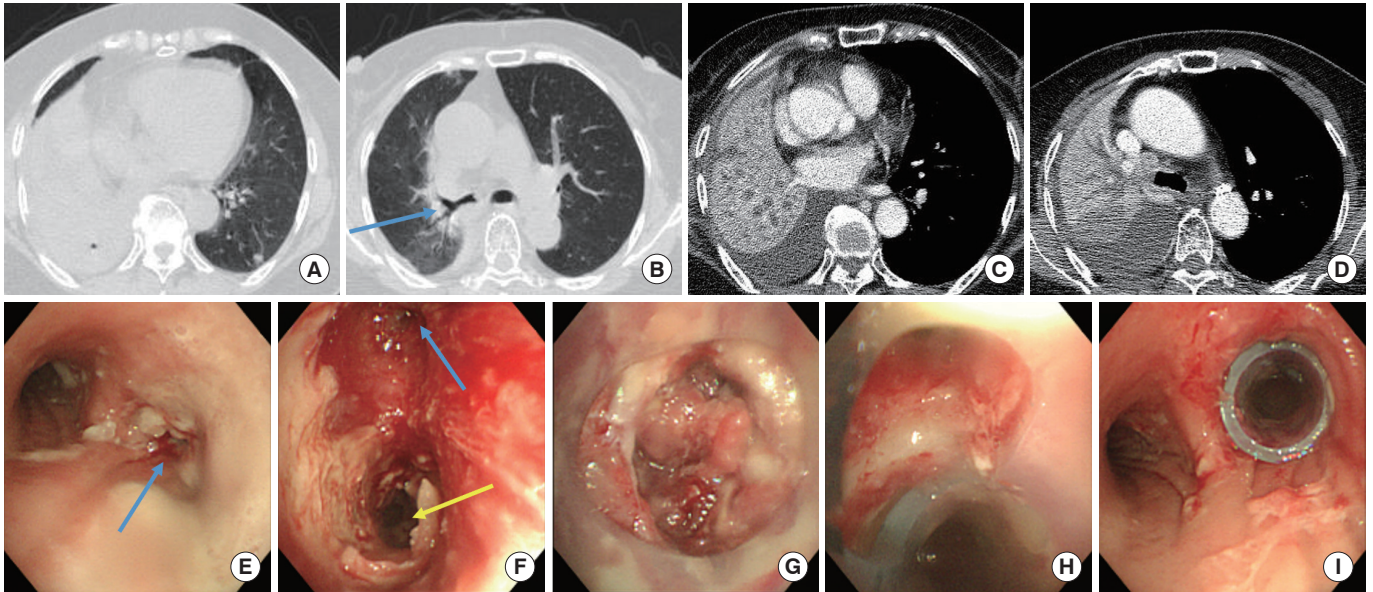
After sufficient confirmation using the images, bronchoscopy is performed to determine the feasibility of bronchoscopic intervention. Flexible bronchoscopy under moderate sedation can be used to assess this condition. However, it can be dangerous because cough suppression may be difficult and respiratory distress can easily occur in patients with MCAO. However, it is safer to assess the airway using flexible bronchoscopy, while maintaining ventilation with a rigid bronchoscope under general anesthesia. Moreover, it is more useful

because bronchoscopic intervention can be performed immediately after confirming the extent of the MCAO. Even if the airway is completely blocked by the mass, the condition of the airway behind the mass can be investigated by injecting saline through the biopsy channel of the flexible bronchoscope between the mass and the airway wall and gently pushing the flexible bronchoscope (Fig. 6). This examination will provide insight concerning the origin of the mass (where to cut) and also provide guidance regarding the extent of the mass. The condition of the airway behind the mass can be simultaneously evaluated. If the airway behind the mass cannot be examined concurrently, it is better not to proceed with bronchoscopic intervention because how far the mass needs to be cut would be unknown.

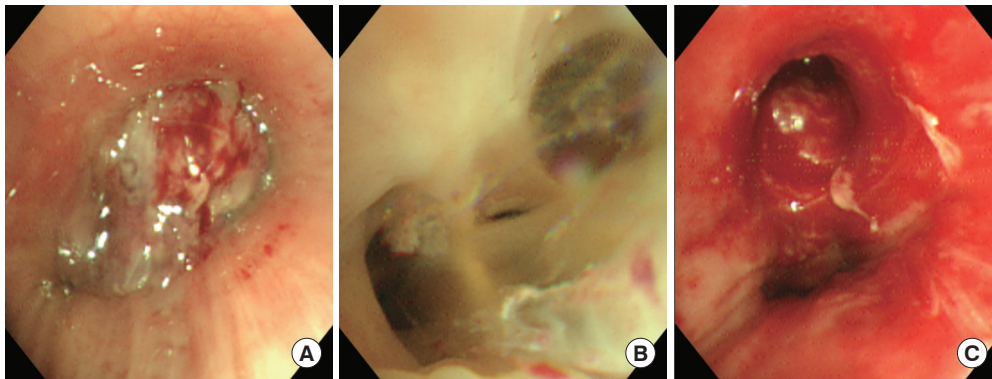
In general, there are a few absolute contraindications to rigid bronchoscopy [4]. First, rigid bronchoscopy is not possible if general anesthesia is contraindicated for reasons such as unstable coronary disease or a poor general condition. Second, there are anatomical concerns. This procedure is impos-



**Fig. 4.** A representative case showing successful treatment. The patient had an additional chemotherapy plan, and the period of complete collapse was short. A 50-year-old man was admitted to the intensive care unit (ICU) due to respiratory distress accompanied by complete atelectasis of the left lung during first-line chemotherapy for lung cancer with multiple metastases (adenocarcinoma without mutations on epidermal growth factor receptor gene and translocations involving anaplastic lymphoma kinase). (A) A computed tomography (CT) scan 2 months previously revealed that the metastatic mediastinal lymph nodes had begun to invade the lateral wall of the left main bronchus at that time (red arrow). (B, C) A CT scan performed after admission to the ICU revealed a mass completely filling the left main bronchus. Since the period of complete collapse of the left lung was less than 2 months and there was a remaining treatment plan (immunotherapy), we implemented an aggressive procedure. However, respiratory failure was severe, so the procedure was performed at the ICU bedside. (D, E, F) The mass filling the inside of the left main bronchus was resected by mechanical debridement using a rigid bronchoscope. (G, H) Stenting was also performed to resolve extrinsic compression. The patients achieved an almost complete response after receiving immunotherapy and radiation therapy. Hence, the stent could be removed 3 months after the procedure. The patient has been living recurrence-free for 7 years.



**Fig. 5.** A representative case showing unfavorable results because the patient had no additional chemotherapy plan and the period of complete collapse was too long. A 74-year-old woman who underwent definitive concurrent chemoradiation therapy for small cell lung cancer (SCLC) was admitted to the intensive care unit (ICU) due to recurrence and worsening dyspnea. (A) A computed tomography (CT) scan 3 months previously revealed that the right middle and right lower lobes (RML/RLL) were already blocked. (B) However, at this time the right upper lobe (RUL) was not blocked (blue arrow) and the patient had no shortness of breath. (C) A CT scan performed after admission to the ICU showed no necrosis and no cut-off sign of blood flow in the RML/RLL, (D) and it was confirmed that the RUL had collapsed within 3 months. Although there had been no additional chemotherapy plans for the recurrent SCLC, we decided to perform the procedure to get the patient out of mechanical ventilation. (E) The gross findings of the rigid bronchoscopy procedure showed that the entrance of the right main bronchus (RMB) was narrowed by tumor invasion and extrinsic compression (blue arrow). (F) The tumor inside the RMB and bronchus intermedius (BI) was removed using mechanical debulking with a rigid bronchoscope, and the RUL (blue arrow) and BI (yellow arrow) were secured. (G) Although the orifices of the RML/RLL could be secured, the inside could not be opened, and a stent had to be inserted. (H, I) The stent with a ventilation hole for the RUL was inserted from the RMB to the end of the BI. After the procedure, the RUL collapse improved, however the RML/RLL collapse was persistent. The patient died of pneumonia 1 week later.



**Fig. 6.** Assessment of the bronchial condition with bronchoscopy in patients with complete obstruction. A 42-year-old woman with breast cancer visited our hospital complaining of dyspnea, and a computed tomography scan revealed complete collapse of the left lung. (A) A mass completely blocking the midpoint of the left main bronchus (LMB) was found on gross examination using rigid bronchoscopy. (B) Saline was injected through the biopsy channel of the flexible bronchoscope into the gap between the mass and the bronchial wall, and the scope was gently pushed into the gap. The scope was able to enter the back side of the tumor, and the bronchial condition was closely observed. Inside the branches of the left lower lobe (LLL) was full of secretions, and there was no tumor invasion, and it was confirmed that the tumor originated at the entrance of the left upper lobe (LUL) and bulged to the left main. The inside of the segmental bronchi of the LLL was full of secretions, and there was no invasion of the tumor. It was confirmed that the tumor grew from the orifice of the LUL and bulged to the LMB. (C) We performed tumor removal and secured both the LUL and LLL.



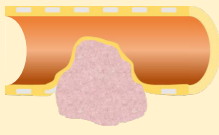


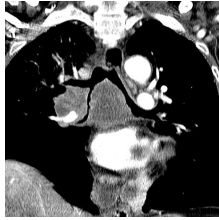
Types		Endoluminal type (Intrinsic stenosis)	Mixed type (Mixed stenosis)	Extraluminal type (Extrinsic stenosis)
Image findings	Mimetic diagram			
	CT images			
Usefulness of each treatment	Laser & debridement	+++	++	-
	Stenting	±	++	+++

Fig. 7. General treatment principles by classification of stenosis. The more plus signs, the stronger the tool for resolving the stenosis. A minus sign means that there is generally no help in resolving the stenosis. A plus-minus sign means that it may be helpful depending on the case. Stent insertion is not generally recommended for resolving the endoluminal type. However, it can be considered for palliative purposes when rapid progression is expected and there is no additional effective treatment plan. CT, computed tomography.

sible in patients with a fused or unstable cervical spine, insufficient mouth opening, and unstable midline facial fractures, because the neck must be hyperextended and rotated, and the mouth needs to be opened wide during intubation with a rigid bronchoscope and during the procedure [16].

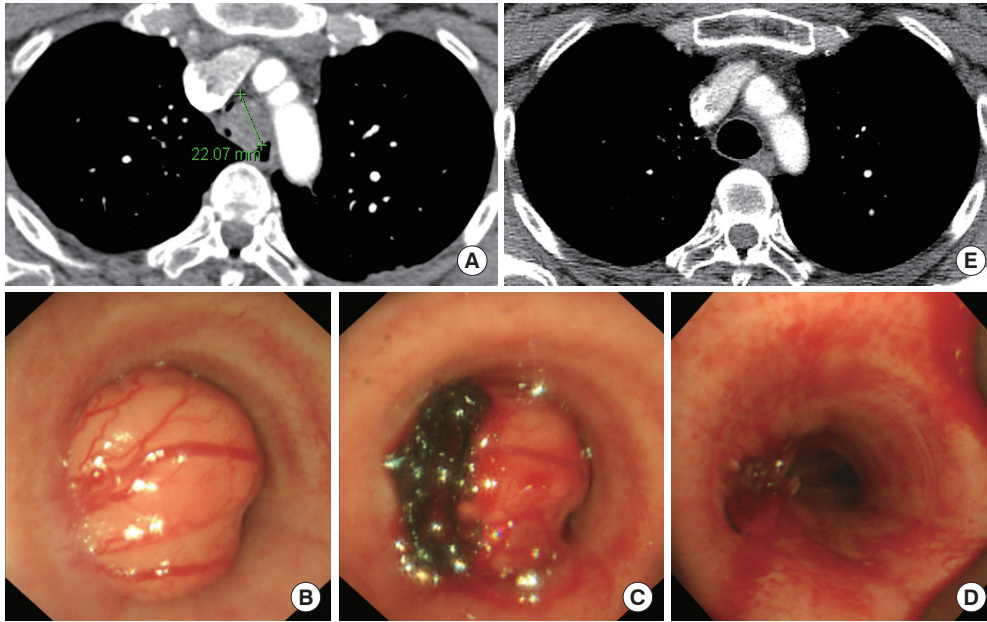
### WHICH IS THE MOST APPROPRIATE TECHNIQUE?

The main treatment modalities for MCAO can be largely divided into removal of the mass, such as laser cauterization or mechanical debridement, and stent insertion to secure and maintain the inner diameter of the airway (Fig. 7) [3,4]. Laser cauterization or mechanical debridement is effective for malignant tissue that has invaded inside the airway, and stent insertion is effective for extrinsic compression from outside the airway. Mixed methods require a suitable combination of these two methods.

Balloon bronchoplasty is also a useful bronchoscopic intervention technique for MCAO. There are reports that ballooning alone can greatly assist in resolving MCAO [17]; however, since there are more effective treatments such as stenting, mechanical debridement, and laser cauterization, ballooning is generally considered an auxiliary procedure. Ballooning can be used as an adjunct to bougienation and mechanical debridement with a rigid bronchoscope itself [4]. It is safer and

more effective to perform bougienation with the rigid bronchoscope itself than with ballooning. One advantage of using a rigid bronchoscope for bougienation is the ability to maintain ventilation, which cannot be achieved with ballooning. In addition, the strong radial force of the balloon can damage the weakest area, such as the posterior membrane of the trachea, whereas bougienation using a rigid bronchoscope can be adjusted by the operator so that less force is applied to a specific region by using its beveled tip. However, if the airway is too narrow to immediately perform bougienation using a rigid bronchoscope, ballooning should be gently performed first. Second, because a rigid bronchoscope cannot enter the upper lobar bronchus, ballooning can be used in this area. Third, ballooning can be used to control bleeding that may occur during the procedure by directly compressing the bleeding focus or by blocking one side of the bronchus to control the bleeding. Depending on the situation, it may be preferable to apply direct pressure at the bleeding site using a rigid bronchoscope. Fourth, sometimes the silicone stent might not unfold after insertion. In such cases, ballooning inside the stent is useful to unfold the stent. Because ballooning can cause bronchial tearing and bleeding [17], it is necessary to select a balloon with a suitable outer diameter and apply the appropriate pressure recommended by the manufacturer.

Although laser ablation is effective for treating endobronchial tumors, it is a time-consuming procedure [18]. There-



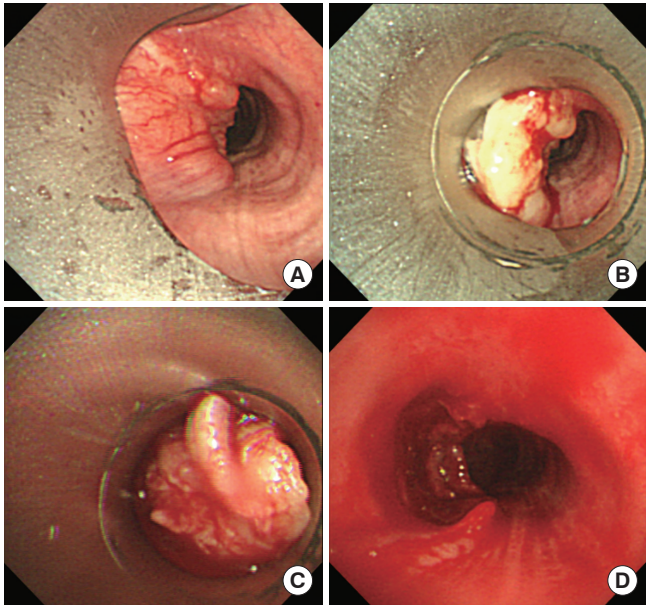
**Fig. 8.** A representative case of adenoid cystic carcinoma (ACC). A 36-year-old woman who continuously received asthma treatment for shortness of breath, showed no response to treatment, and the shortness of breath gradually worsened. (A) A computed tomography scan showed an endobronchial tumor with a diameter of approximately 2 cm in the mid-trachea region. A biopsy using flexible bronchoscopy was not performed due to concerns about the possibility of bleeding and potential difficulties in maintaining ventilation during the procedure. Rigid bronchoscopy was immediately performed. (B) The tumor originated from the left lateral wall of the mid-trachea. (C) After laser cauterization for the margin of the tumor, mechanical debriement was performed with a rigid bronchoscope. (D, E) The normal internal diameter of the trachea was obtained. ACC was confirmed; however, the patient refused surgery, and received definitive radiation therapy. After 2 years, lung metastasis occurred, which has been progressing very slowly without additional chemotherapy for 5 years thus far.

fore, it is unsuitable for patients with severe obstruction or difficulty maintaining ventilation. In general, laser therapy is performed to easily core out the tumor mass with a rigid tube by cauterizing the boundary between the tumor and normal mucosa before mechanical debriement (Fig. 8) [19]. In addition, it is performed to control bleeding at the base of the tumor after resection. Recent reports have shown that cryorecanalization using cryotherapy is safe and effective for treating patients with MCAO [20-23]. However, cryotherapy can occasionally cause massive bleeding. Therefore, caution should be exercised.

As previously mentioned, one of the main advantages of rigid bronchoscopy is that certain important techniques, such as mechanical debriement and silicone stent insertion are not possible with flexible bronchoscopy, and can only be achieved with rigid bronchoscopy. In particular, mechanical debriement using the beveled tip of a rigid bronchoscope is very effective because it can remove an endobronchial mass within minutes [3,4,19]. However, caution is required to avoid complications such as bronchial perforation and bleeding. In addition, because the field of view is obscured by the mass during debriement, it is necessary to thoroughly evaluate

the length of the tumor and the direction of entry, and the procedure should be completed simultaneously (Fig. 9). To remove the obstructing mass by mechanical debriement (also called core out, debulking, or blunt dissection) using a rigid bronchoscope, the beveled tip of the scope is placed against the base of the lesion with a gentle twisting motion and forward pressure. The bluntly dissected fragments are then removed using suction or rigid forceps.

Stents are largely classified as metallic or silicone depending on the material of which they are comprised. Metallic stents possess the advantage of easy insertion even with flexible bronchoscopy under moderate sedation [24]. However, serious complications such as stent fracture can occasionally occur, and excessive granulation tissue formation frequently occurs [24-27]. Moreover, stent removal is generally difficult to achieve. Silicone stents have the disadvantage of being inserted only through a rigid bronchoscope under general anesthesia, but are easily removed. Although metallic stents have greatly improved due to recent technological developments of materials, we believe that the advantages of silicone stents are greater, regarding long-term management [28,29]. Because the stent is a foreign body in the bronchus and disrupts



**Fig. 9.** Mechanical debriement using rigid bronchoscope. Before planning the definitive treatment of a 54-year-old male patient with tracheal adenoid cystic carcinoma, rigid bronchoscopy was performed to resolve dyspnea. (A) The location and length of the tumor were confirmed while observing the distal part of the tumor using flexible bronchoscopy. (B) The tip of the rigid bronchoscope was used for tumor resection. (C) As the tumor was being excised, the field of view began to be obscured by the truncating tumor. Therefore, before initiating mechanical debriement, it is necessary to carefully plan in which direction and how much to push the rigid bronchoscope to ensure a safe and perfect cut. Misdirection of the rigid bronchoscope can lead to complications such as pneumothorax, pneumomediastinum, or bleeding due to bronchial perforation. In addition, if the tumor is sufficiently large, the airway can be blocked by the truncated tumor itself, which must be quickly pulled out with rigid forceps or suction. (D) After removing the tumor, the procedure was completed without complications, such as perforation or massive bleeding.

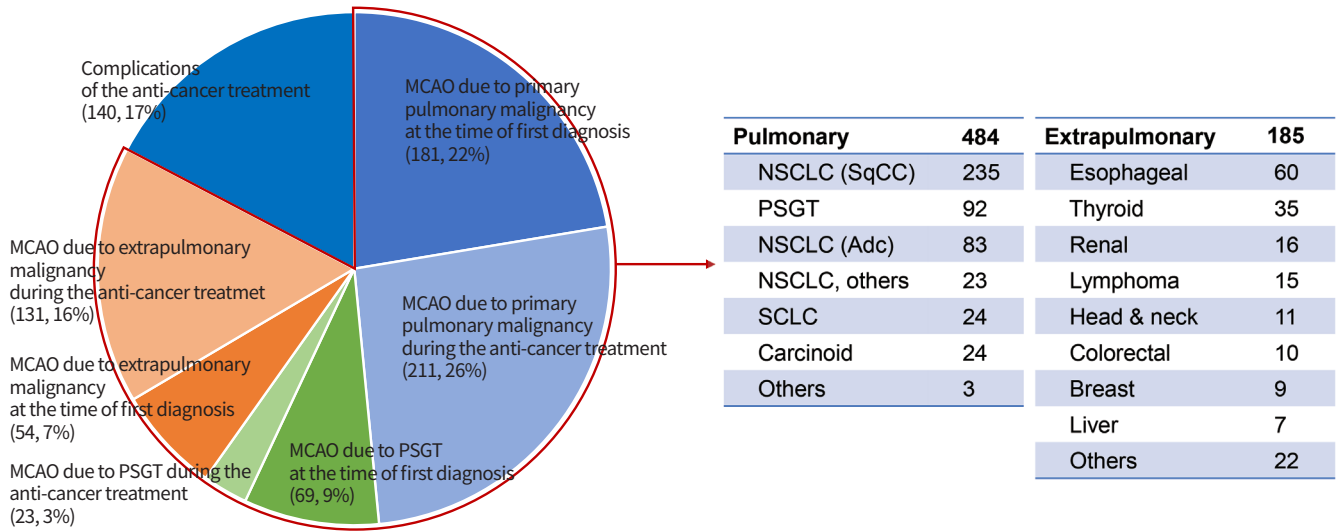
the natural mucociliary clearance mechanism of the airway, mucostasis may cause odor or stent blockage over the long-term [30,31]. Therefore, stent insertion should be performed only when extrinsic compression is clearly present, and the airway lumen cannot be secured by removing the endobronchial tumor only. In a multicenter randomized controlled trial on the effect of stenting in patients with MCAO, although recruitment failed to reach the target number of patients, the stenting group exhibited a better dyspnea score, and less recurrence of obstruction and need for additional bronchoscopic intervention for 1 year, compared to the non-stenting group [32]. However, this effect was unclear in treatment-naïve patients. In other words, stenting was more effective after failure of first-line chemotherapy, and was not recommended for patients without previous oncological treatment.

According to two survey studies conducted in the United States and Europe, there are significant heterogeneities in post-stenting management, such as surveillance imaging tests, bronchoscopy, nebulized treatments, and expectorants [5,33]. Further studies are required to provide evidence and propose guidelines addressing this topic. However, based on our experience, we recommend digital tomosynthesis and spirometry for routine surveillance after the procedure. In our previous study, digital tomosynthesis demonstrated greater sensitivity and accuracy than simple chest radiography to identify silicone airway stents and silicone stent-related complications [34]. Moreover, the patient is exposed to a lower radiation dose than in CT. It is well known that forced expiratory volume in 1 second ( $FEV_1$ ) and forced vital capacity (FVC) increase on spirometry after a successful procedure [35,36]. Conversely, if restenosis occurs after the procedure,  $FEV_1$  and FVC may decrease. Moreover, the change in the flow-volume curve identifies the region that has a problem [37]. Routine surveillance bronchoscopy and oral expectorants do not appear to be very effective and nebulized treatments may aid in preventing mucostasis.

### IN WHICH CASES IS THE PROCEDURE MORE “HELPFUL”?

Fig. 10 shows the indications for rigid bronchoscopy in 847 patients with malignant diseases between 2004 and 2020 at the SMC. We focused on rigid bronchoscopic intervention for MCAO, excluding procedures for fistula or radiation-induced bronchial stenosis that occurred secondary to anti-cancer treatment, and procedures for cancer limited to the bronchial mucosa without CAO. MCAO can be divided into primary pulmonary and extrapulmonary malignancies, depending on the type of cancer. In MCAO due to primary pulmonary malignancy, squamous cell carcinoma was the most common, at 49% (235/484), followed by pulmonary salivary gland-type tumors (PSGTs), such as adenoid cystic carcinoma and mucoepidermoid carcinoma, at 19% (92/484). Although PSGT accounts for <1% of all lung cancers [38], interventional pulmonologists often encounter PSGT in clinical practice because it primarily occurs in the mucosa of the central airway. In MCAO due to extrapulmonary malignancy, esophageal cancer was the most common (32%, 60/185), followed by thyroid cancer (19%, 35/185). In addition, MCAO can be divided into MCAO discovered at the first diagnosis and MCAO identified during anti-cancer treatment, depending on the time of occurrence of the CAO. Among MCAOs due to primary pulmonary and ex-





**Fig. 10.** Indications for rigid bronchoscopy in patients with malignancies at Samsung Medical Center between 2004 and 2020. Complications of the anti-cancer treatment included postoperative tracheobronchial stenosis, post-radiation bronchitis stenosis, and airway fistula. MCAO, malignant central airway obstruction; PSGT, pulmonary salivary gland-type tumor; NSCLC, non-small cell lung cancer; SqCC, squamous cell carcinoma; Adc, adenocarcinoma; SCLC, small cell lung cancer.

trapulmonary malignancies, CAO was detected with the first diagnosis of cancer in 52% (250/484) and 29% (54/185) of cases, respectively. This means that many patients had MCAO at the first diagnosis of cancer and were able to gain time to receive definitive therapy using rigid bronchoscopy as a bridge therapy (Fig. 8).

Bronchoscopic intervention can improve the quality of life, including the dyspnea score, and may gain time for definitive treatment, such as surgery, chemotherapy, and radiation therapy [35,36,39-42]. However, survival benefit cannot be achieved in all patients with MCAO; therefore, patient selection is important. In general, the survival rate improves in treatment-naïve patients [42,43]. However, with the recent development of targeted therapy, if there is a remaining anti-cancer treatment plan even in patients with progressive disease, a good long-term prognosis can be obtained after rigid bronchoscopy resolves the emergency situation (Fig. 4) [43-45].

Overall survival after the procedure was higher in patients with endobronchial obstruction and a good performance status [42-44]. In particular, complete resection using rigid bronchoscopy is feasible in certain airway mucosal tumors without submucosal invasion (e.g., endobronchial carcinoid tumors, papillomatous squamous cell carcinoma, airway mucosal metastasis from renal cell carcinoma, and breast cancer) [46-48]. Moreover, in the case of extrapulmonary carcinoma, patients with MCAO due to thyroid cancer or lymphoma,

which are generally known to respond well to chemotherapy, have a good prognosis [44]. Technical success, defined as securing an airway lumen of 50% or more, is generally achieved in over 90% of patients following bronchoscopic intervention [35,42-44,49]. In particular, better technical success can be achieved in patients with good performance status and endobronchial obstruction, those who underwent stent insertion, and those without airway fistulas [35]. Acute complications related to the procedure include bleeding and respiratory distress, which occur in <10% of patients [35,39,43,44]. Acute complications are more likely to occur in cases of emergency procedures, repeat procedures, or moderate sedation (rather than general anesthesia) [49]. Procedure-related mortality is rare [39,43,44,49]. However, most of these studies were conducted at proficient institutions, that performed a large number of procedures. Significant variations in technical success rates (90% to 98%), complication rates (0.9% to 11.7%), and 30-day mortality (7.7% to 20.2%) were observed among hospitals [35,49]. These significant variations are believed to be related to differences in technical proficiency and patient selection among hospitals, and to the lack of systematic guidelines regarding the procedure.

Interventional pulmonologists frequently encounter PSGT, which mainly occurs in the mucosa of the central airway. Because dyspnea on exertion and resting dyspnea generally occur when the cross-sectional area of the trachea is narrowed by more than 75% and 90%, respectively [10], in many cases,

patients with PSGT visit the hospital just before respiratory failure. Even in such cases, rigid bronchoscopy can be useful as a bridge therapy preceding definitive treatment (Fig. 8) [39]. In addition, because PSGT progresses very slowly, even if the stage is advanced, good long-term survival can be achieved by managing CAO with bronchoscopic intervention [39].

## CONCLUSION

In the field of bronchoscopic intervention, rigid bronchoscopy has the advantage of enabling safer performance of various procedures compared to flexible bronchoscopy. As anti-cancer treatment outcomes have improved over the past decade and the number of patients presenting with MCAO has increased, many interventional pulmonologists have gained interest in this procedure. However, appropriate patient selection is important, because the procedure is not useful for all patients with MCAO. When considering technical possibilities, it is better if the obstruction is limited to the central airway without complications of the distal airway, lung parenchyma, or vessels. When deciding whether the patient would benefit, it is better if the patient is first diagnosed or has an additional anti-cancer treatment option. Although 30 to 40 years have elapsed since modern interventional bronchoscopy was introduced, the technique is not standardized. However, the basic principle that MCAO should be treated by mechanical debulking or laser cauterization for endobronchial tumors and by stenting for extrinsic compression is not expected to change in the future. Future efforts should focus on the standardization of detailed techniques and on providing ongoing training.

## CONFLICTS OF INTEREST

No potential conflict of interest relevant to this article was reported.

## ORCID

Byeong-Ho Jeong <https://orcid.org/0000-0002-3124-1718>  
Hojoong Kim <https://orcid.org/0000-0001-9207-0433>

## AUTHOR CONTRIBUTIONS

Conception or design: BHJ, HK.

Acquisition, analysis, or interpretation of data: BHJ, HK.

Drafting the work or revising: BHJ, HK.

Final approval of the manuscript: BHJ, HK.

## REFERENCES

1. Dumon JF, Reboud E, Garbe L, Aucomte F, Meric B. Treatment of tracheobronchial lesions by laser photoresection. *Chest* 1982;81:278-84.
2. Dumon JF. A dedicated tracheobronchial stent. *Chest* 1990;97:328-32.
3. Dutau H, Vandemoortele T, Breen DP. Rigid bronchoscopy. *Clin Chest Med* 2013;34:427-35.
4. Batra H, Yarmus L. Indications and complications of rigid bronchoscopy. *Expert Rev Respir Med* 2018;12:509-20.
5. Dutau H, Breen D, Bugalho A, Dalar L, Daniels J, Dooms C, et al. Current practice of airway stenting in the adult population in Europe: a survey of the European Association of Bronchology and Interventional Pulmonology (EABIP). *Respiration* 2018;95:44-54.
6. Kim HJ. Airway silicone stenting in the management of tracheobronchial stenosis. *Tuberc Respir Dis* 2007;62:95-7.
7. Jeong BH, Lee SH, Kim HH, Yoon HI, Eom JS, Park YS, et al. Trends and an online survey on the use of rigid bronchoscopy in Korea. *J Korean Med Sci* 2023;38:e13.
8. Cavaliere S, Venuta F, Foccoli P, Toninelli C, La Face B. Endoscopic treatment of malignant airway obstructions in 2,008 patients. *Chest* 1996;110:1536-42.
9. Cavaliere S, Foccoli P, Farina PL. Nd:YAG laser bronchoscopy: a five-year experience with 1,396 applications in 1,000 patients. *Chest* 1988;94:15-21.
10. Brouns M, Jayaraju ST, Lacor C, De Mey J, Noppen M, Vincken W, et al. Tracheal stenosis: a flow dynamics study. *J Appl Physiol* (1985) 2007;102:1178-84.
11. Greelish JP, Friedberg JS. Secondary pulmonary malignancy. *Surg Clin North Am* 2000;80:633-57.
12. Saji H, Furukawa K, Tsutsui H, Tsuboi M, Ichinose S, Usuda J, et al. Outcomes of airway stenting for advanced lung cancer with central airway obstruction. *Interact Cardiovasc Thorac Surg* 2010;11:425-8.
13. Kang MJ, Won YJ, Lee JJ, Jung KW, Kim HJ, Kong HJ, et al. Cancer statistics in Korea: incidence, mortality, survival, and prevalence in 2019. *Cancer Res Treat* 2022;54:330-44.
14. Mitchell PD, Kennedy MP. Bronchoscopic management of malignant airway obstruction. *Adv Ther* 2014;31:512-38.
15. Lim SY, Park HK, Jeon K, Um SW, Koh WJ, Suh GY, et al. Factors predicting outcome following airway stenting for post-tuberculosis tracheobronchial stenosis. *Respirology*

- 2011;16:959-64.
16. Pathak V, Welsby I, Mahmood K, Wahidi M, MacIntyre N, Shofer S. Ventilation and anesthetic approaches for rigid bronchoscopy. *Ann Am Thorac Soc* 2014;11:628-34.
  17. Hautmann H, Gamarra F, Pfeifer KJ, Huber RM. Fiberoptic bronchoscopic balloon dilatation in malignant tracheobronchial disease: indications and results. *Chest* 2001; 120:43-9.
  18. Mahajan AK, Ibrahim O, Perez R, Oberg CL, Majid A, Folch E. Electrosurgical and laser therapy tools for the treatment of malignant central airway obstructions. *Chest* 2020; 157:446-53.
  19. Flannery A, Daneshvar C, Dutau H, Breen D. The art of rigid bronchoscopy and airway stenting. *Clin Chest Med* 2018;39:149-67.
  20. Jeong JH, Kim J, Choi CM, Ji W. Clinical outcomes of bronchoscopic cryotherapy for central airway obstruction in adults: an 11-years' experience of a single center. *J Korean Med Sci* 2023;38:e244.
  21. Inaty H, Folch E, Berger R, Fernandez-Bussy S, Chatterji S, Alape D, et al. Unimodality and multimodality cryodebridement for airway obstruction: a single-center experience with safety and efficacy. *Ann Am Thorac Soc* 2016; 13:856-61.
  22. Perikleous P, Mayer N, Finch J, Beddow E, Anikin V, Asadi N. Treatment of pulmonary carcinoid tumors with bronchoscopic cryotherapy: a 28-year single-center experience. *J Bronchology Interv Pulmonol* 2022;29:71-82.
  23. Schumann C, Hetzel M, Babiak AJ, Hetzel J, Merk T, Wibmer T, et al. Endobronchial tumor debulking with a flexible cryoprobe for immediate treatment of malignant stenosis. *J Thorac Cardiovasc Surg* 2010;139:997-1000.
  24. Dutau H, Musani AI, Plojoux J, Laroumagne S, Astoul P. The use of self-expandable metallic stents in the airways in the adult population. *Expert Rev Respir Med* 2014;8: 179-90.
  25. Jeong BH, Ng J, Jeong SH, Kim H. Clinical outcomes of complications following self-expandable metallic stent insertion for benign tracheobronchial stenosis. *Medicina (Kaunas)* 2020;56:367.
  26. Gompelmann D, Eberhardt R, Schuhmann M, Heussel CP, Herth FJ. Self-expanding Y stents in the treatment of central airway stenosis: a retrospective analysis. *Ther Adv Respir Dis* 2013;7:255-63.
  27. Alazemi S, Lunn W, Majid A, Berkowitz D, Michaud G, Feller-Kopman D, et al. Outcomes, health-care resources use, and costs of endoscopic removal of metallic airway stents. *Chest* 2010;138:350-6.
  28. Guibert N, Saka H, Dutau H. Airway stenting: technological advancements and its role in interventional pulmonology. *Respirology* 2020;25:953-62.
  29. Fortin M, Lacasse Y, Elharrar X, Tazi-Mezalek R, Laroumagne S, Guinde J, et al. Safety and efficacy of a fully covered self-expandable metallic stent in benign airway stenosis. *Respiration* 2017;93:430-5.
  30. Verma A, Um SW, Koh WJ, Suh GY, Chung MP, Kwon OJ, et al. Long-term tolerance of airway silicone stent in patients with post-tuberculosis tracheobronchial stenosis. *ASAIO J* 2012;58:530-4.
  31. Chen DF, Chen Y, Zhong CH, Chen XB, Li SY. Long-term efficacy and safety of the Dumon stent for benign tracheal stenosis: a meta-analysis. *J Thorac Dis* 2021;13:82-91.
  32. Dutau H, Di Palma F, Thibout Y, Febvre M, Cellerin L, Naudin F, et al. Impact of silicone stent placement in symptomatic airway obstruction due to non-small cell lung cancer: a French multicenter randomized controlled study: the SPOC trial. *Respiration* 2020;99:344-52.
  33. Wayne MT, Ali MS, Wakeam E, Maldonado F, Yarmus LB, Prescott HC, et al. Current practices in airway stent management: a national survey of US practitioners. *Respiration* 2023;102:608-12.
  34. Kim BG, Chung MJ, Jeong BH, Kim H. Diagnostic performance of digital tomosynthesis to evaluate silicone airway stents and related complications. *J Thorac Dis* 2021; 13:5627-37.
  35. Ost DE, Ernst A, Grosu HB, Lei X, Diaz-Mendoza J, Slade M, et al. Therapeutic bronchoscopy for malignant central airway obstruction: success rates and impact on dyspnea and quality of life. *Chest* 2015;147:1282-98.
  36. Mahmood K, Wahidi MM, Thomas S, Argento AC, Ninan NA, Smathers EC, et al. Therapeutic bronchoscopy improves spirometry, quality of life, and survival in central airway obstruction. *Respiration* 2015;89:404-13.
  37. Ko Y, Yoo JG, Yi CA, Lee KS, Jeon K, Um SW, et al. Changes in the flow-volume curve according to the degree of stenosis in patients with unilateral main bronchial stenosis. *Clin Exp Otorhinolaryngol* 2015;8:161-6.
  38. Falk N, Weissferdt A, Kalhor N, Moran CA. Primary pulmonary salivary gland-type tumors: a review and update. *Adv Anat Pathol* 2016;23:13-23.
  39. Kim BG, Lee K, Um SW, Han J, Cho JH, Kim J, et al. Clinical outcomes and the role of bronchoscopic intervention in patients with primary pulmonary salivary gland-type tumors. *Lung Cancer* 2020;146:58-65.

40. Colt HG, Harrell JH. Therapeutic rigid bronchoscopy allows level of care changes in patients with acute respiratory failure from central airways obstruction. *Chest* 1997; 112:202-6.
41. Oki M, Saka H, Hori K. Airway stenting in patients requiring intubation due to malignant airway stenosis: a 10-year experience. *J Thorac Dis* 2017;9:3154-60.
42. Ong P, Grosu HB, Debiante L, Casal RF, Eapen GA, Jimenez CA, et al. Long-term quality-adjusted survival following therapeutic bronchoscopy for malignant central airway obstruction. *Thorax* 2019;74:141-56.
43. Kim BG, Shin B, Chang B, Kim H, Jeong BH. Prognostic factors for survival after bronchoscopic intervention in patients with airway obstruction due to primary pulmonary malignancy. *BMC Pulm Med* 2020;20:54.
44. Shin B, Chang B, Kim H, Jeong BH. Interventional bronchoscopy in malignant central airway obstruction by extra-pulmonary malignancy. *BMC Pulm Med* 2018;18:46.
45. Jeon K, Kim H, Yu CM, Koh WJ, Suh GY, Chung MP, et al. Rigid bronchoscopic intervention in patients with respiratory failure caused by malignant central airway obstruction. *J Thorac Oncol* 2006;1:319-23.
46. Brokx HA, Risse EK, Paul MA, Grunberg K, Golding RP, Kunst PW, et al. Initial bronchoscopic treatment for patients with intraluminal bronchial carcinoids. *J Thorac Cardiovasc Surg* 2007;133:973-8.
47. Bertoletti L, Elleuch R, Kaczmarek D, Jean-Francois R, Vergnon JM. Bronchoscopic cryotherapy treatment of isolated endoluminal typical carcinoid tumor. *Chest* 2006; 130:1405-11.
48. Inoue Y, Oka M, Ishii H, Kimino K, Kishikawa M, Ito M, et al. A solitary bronchial papilloma with malignant changes. *Intern Med* 2001;40:56-60.
49. Ost DE, Ernst A, Grosu HB, Lei X, Diaz-Mendoza J, Slade M, et al. Complications following therapeutic bronchoscopy for malignant central airway obstruction: results of the AQUiRE registry. *Chest* 2015;148:450-71.